

BIO PADTM



CASE REPORT STUDIES



ANGELINI

BIOPADTM



CASE SERIES **ANALYSIS**



ANGELINI

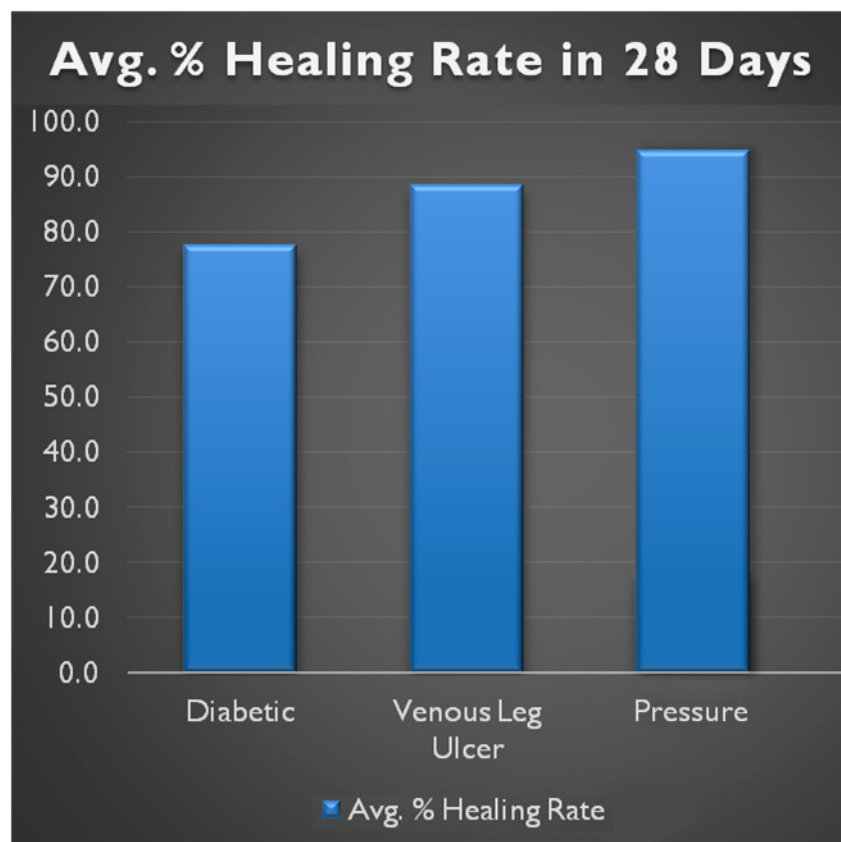
CASE SERIES

ANALYSIS

Wound Healing Rates

Wound healing rates were tracked for 28 days in patients with Chronic non-healing wounds using BioPad Equine Collagen Dressing as a primary wound dressing.

Total Average Healing Rate of 87% was achieved in 3 chronic wound types; Diabetic Ulcers, Venous Leg Ulcers, and Pressure Ulcers.



CASE SERIES

DIABETIC ULCERS

Age of Patient: 53

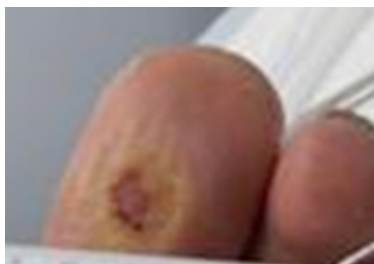Wound Location: Left Plantar Great Toe

Age of Wound: 4.5 years

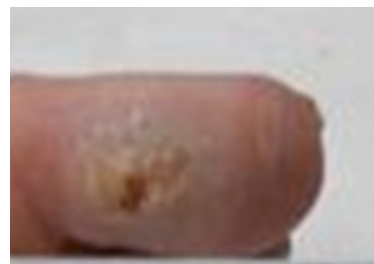Co-morbidities: Diabetes, CAD, CHF, CVI

Previous Treatments: SOC, Apligrath, HBO, Endoform

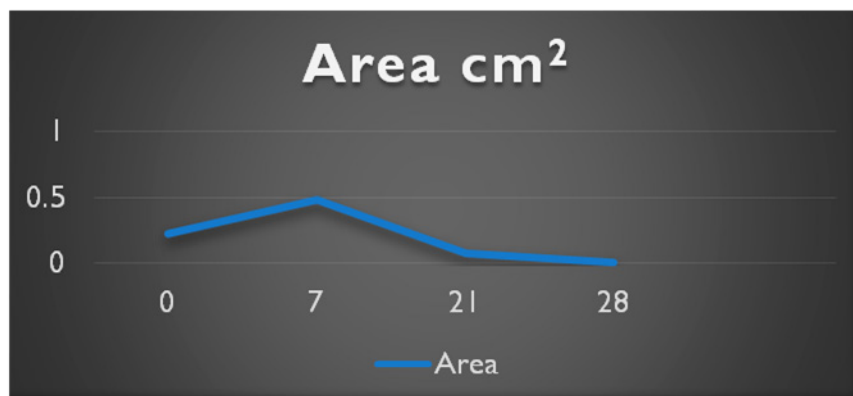
Current Treatments: BioPad



Day 0



Day 28



CASE SERIES

DIABETIC ULCERS

Age of Patient: 65

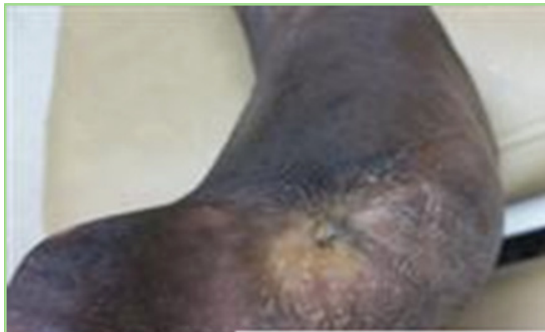
Wound Location: Right Great Toe Amp. Site

Age of Wound: 2 years

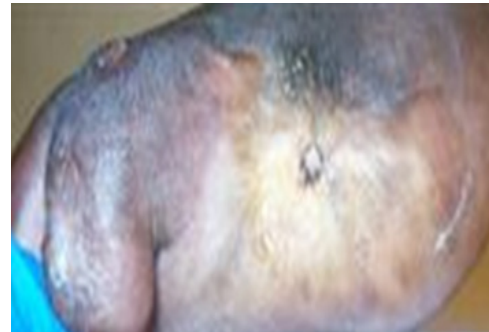Co-morbidities: Diabetes, Hypertension, DVT

Previous Treatments: SOC, NPWT, Dermagraft, Medi-honey, Hypochlorous Acid

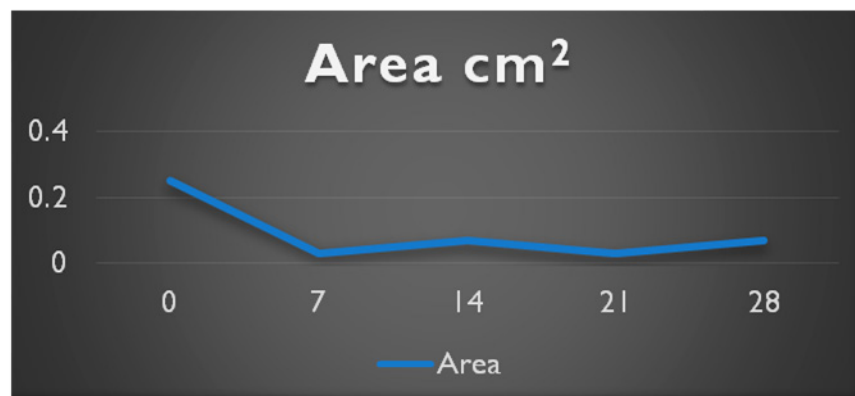
Current Treatments: BioPad



Day 0



Day 28



CASE SERIES

DIABETIC ULCERS

Age of Patient: 79

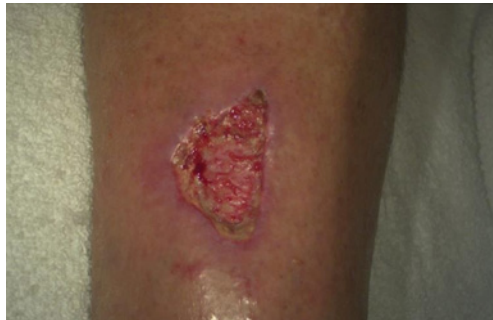Wound Location: Right Lower Extremity

Age of Wound: 2 weeks

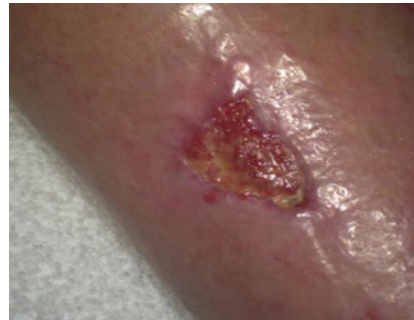Co-morbidities: Diabetes, CAD, CABG, Hypertension, Melanoma, Hyperlipidemia

Previous Treatments: SOC, HBO, IV Antibiotics, Endoform, Oasis, Prisma, Santyl

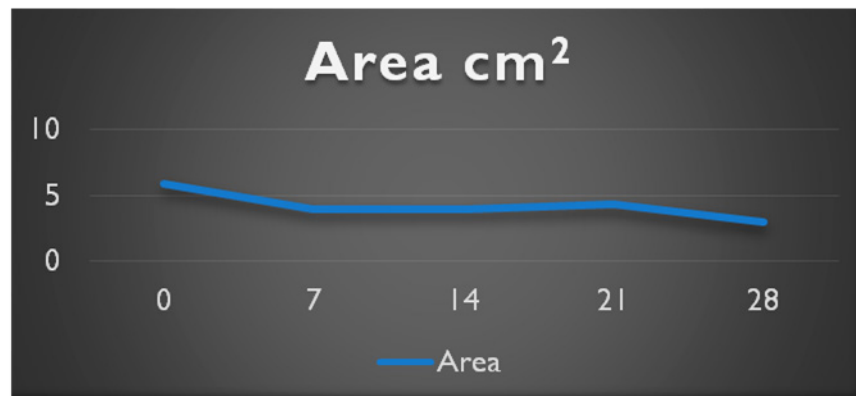
Current Treatments: BioPad, HBO



Day 0



Day 28



CASE SERIES

DIABETIC ULCERS

Age of Patient: 54

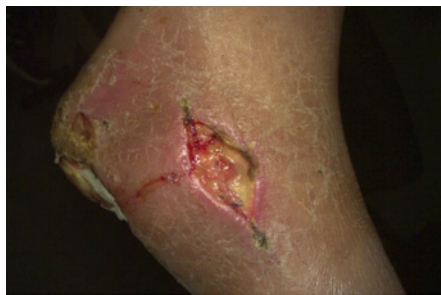Wound Location: Left Ankle

Age of Wound: 2 Months

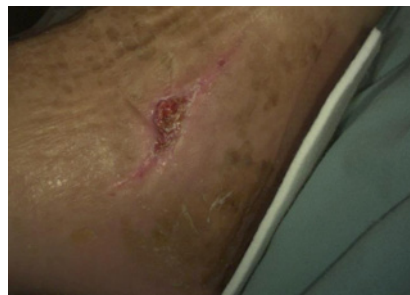Co-morbidities: Diabetes, PAD

Previous Treatments: SOC, HBO, IV Antibiotics


Current Treatments: BioPad



Day 0



Day 28



BIOPADTM



CASE SERIES

VENEOUS LEG ULCERS



ANGELINI

CASE SERIES

VENEOUS LEG ULCERS

Age of Patient: 93

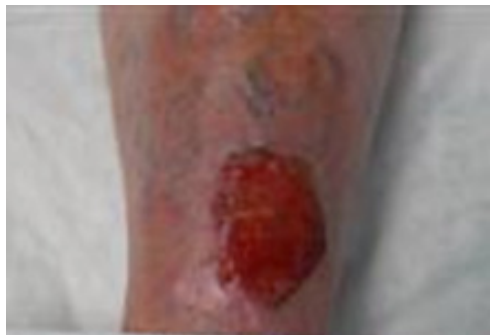Wound Location: Left Anterior Leg

Age of Wound: 2 Months

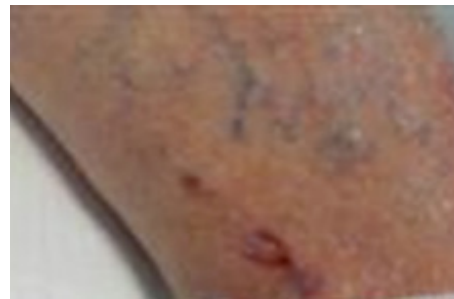Co-morbidities: CVI, CABG, A-Fib. TIA

Previous Treatments: Tubigrip Compression, Santyl, Calcium Alginate

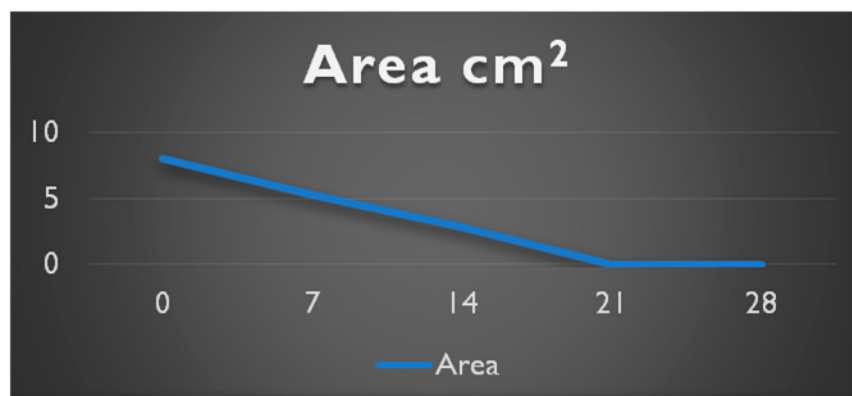
Current Treatments: BioPad, Unnaboot



Day 0



Day 28



CASE SERIES

VENEOUS LEG ULCERS

Age of Patient: 48

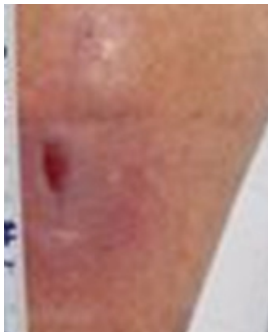Wound Location: Left Medial Lower Leg

Age of Wound: 3.5 Months

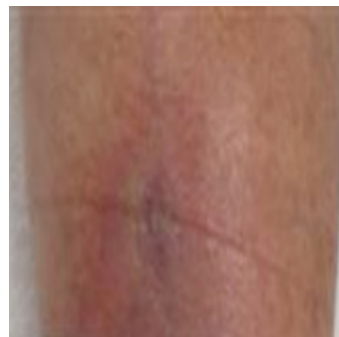Co-morbidities: CVI, DVT Left Leg

Previous Treatments: Compression, Silver Alginate, Systemic Antibiotics, Xeroform

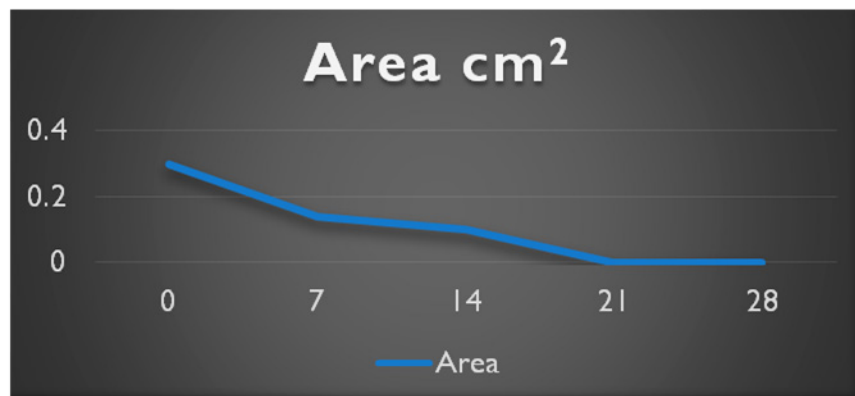
Current Treatments: BioPad



Day 0



Day 28



CASE SERIES

VENEOUS LEG ULCERS

Age of Patient: 37

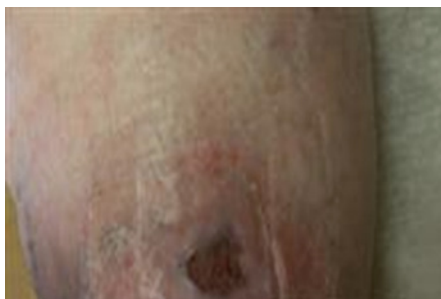Wound Location: Left Lateral Low Gaiter

Age of Wound: 5 Years

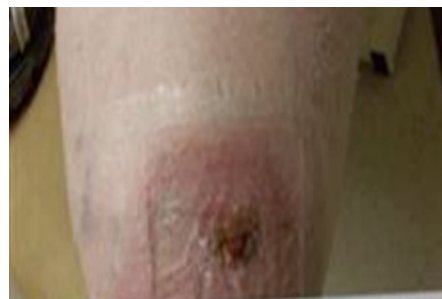Co-morbidities: CVI, CHF, Hypertension Neuropathy, Obesity, Hepatitis A, Hepatitis B

Previous Treatments: Compression, Hypochlorous Acid, Epifix

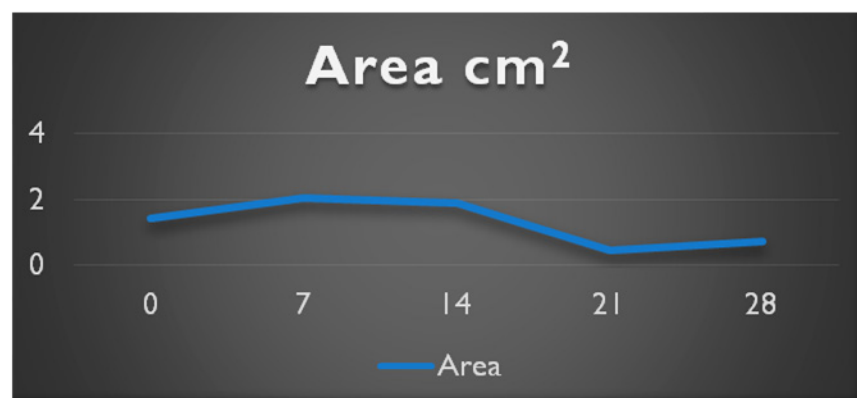
Current Treatments: BioPad, Coban 2 Compression



Day 0



Day 28



CASE SERIES

VENEOUS LEG ULCERS

Age of Patient: 76

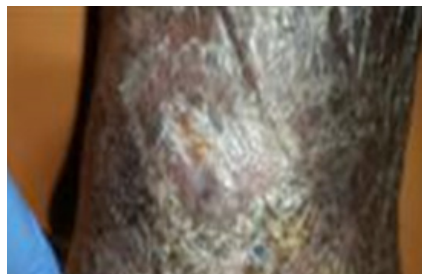Wound Location: Right Posterior Ankle

Age of Wound: 1 Month

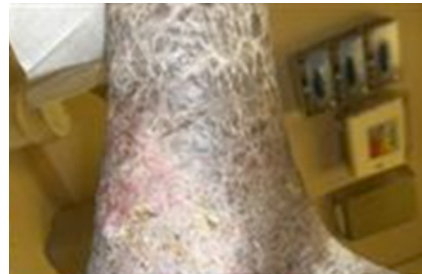Co-morbidities: CVI, PVD, Hypertension

Previous Treatments: Compression, Hypochlorous Acid, Hydrofera Blue

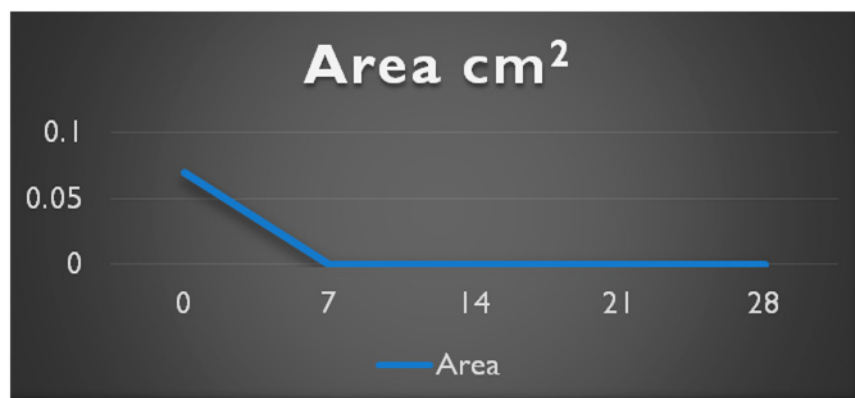
Current Treatments: BioPad, Coban 2 Compression



Day 0



Day 28



CASE SERIES

VENEOUS LEG ULCERS

Age of Patient: 89

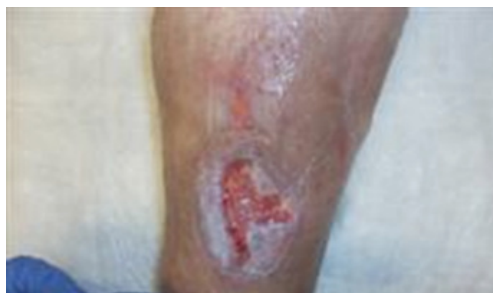Wound Location: Left Anterior Gaiter

Age of Wound: 6 Month

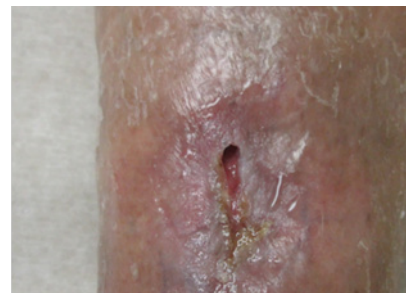Co-morbidities: CVI, CHF, Diabetes, Breast Cancer, Renal Disease, MI

Previous Treatments: Compression, Hypochlorous Acid, Hydrofera Blue

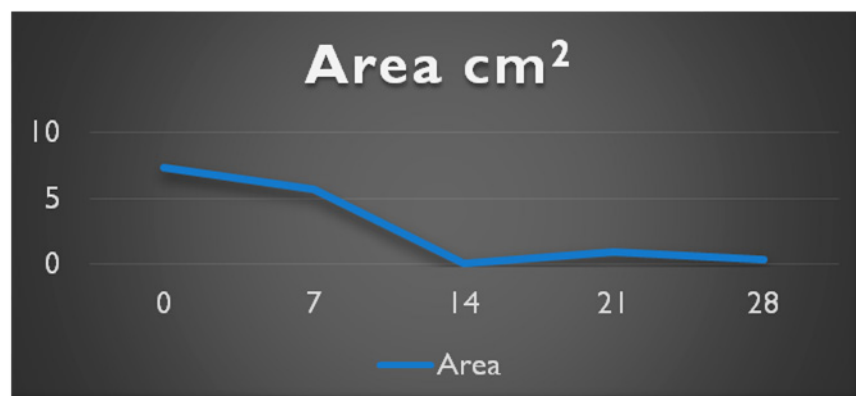
Current Treatments: BioPad, Coban 2 Compression



Day 0



Day 28



CASE SERIES

VENEOUS LEG ULCERS

Age of Patient: 71

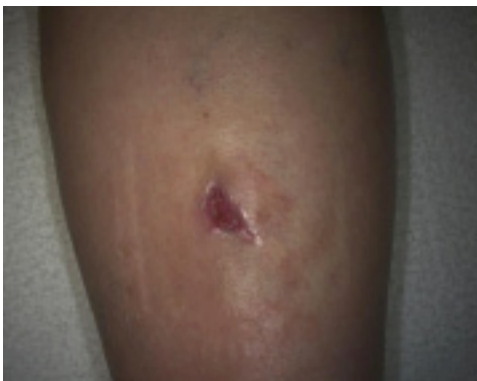Wound Location: Left Medial Leg

Age of Wound: 6 Weeks

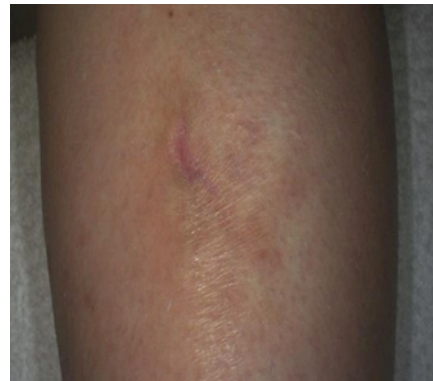Co-morbidities: Hypothyroid, CAD, Hypertension

Previous Treatments: Santyl, Silver Alginate, 3M Coban 2 Compression

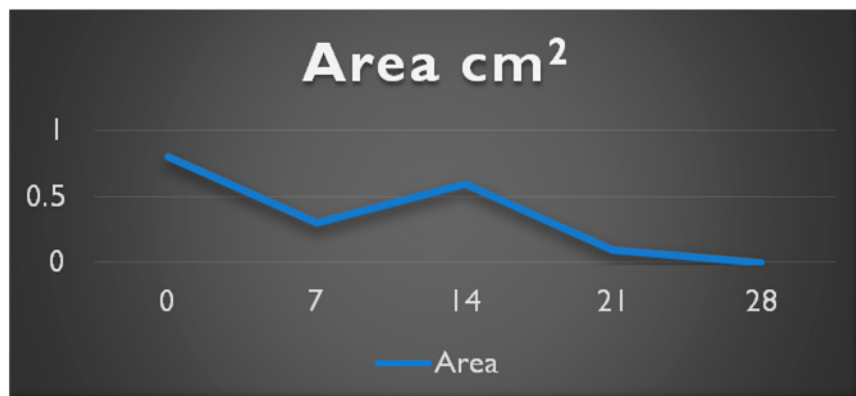
Current Treatments: BioPad, Coban 2 Compression



Day 0



Day 28



BIOPADTM



CASE SERIES

PRESSURE



ANGELINI

CASE SERIES

PRESSURE

Age of Patient: 82

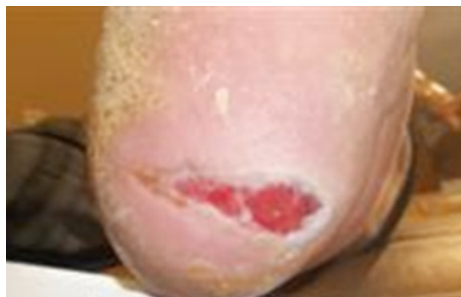Wound Location: Left Plantar Heel

Age of Wound: 6 Months

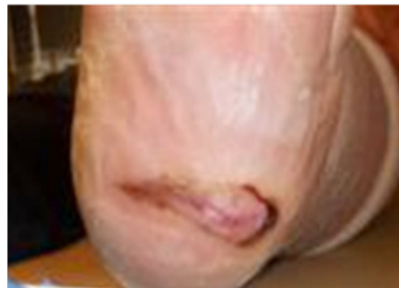Co-morbidities: Colectomy

Previous Treatments: Debridement, CelluTome, Off Loading, Collagen, Silver Alginate

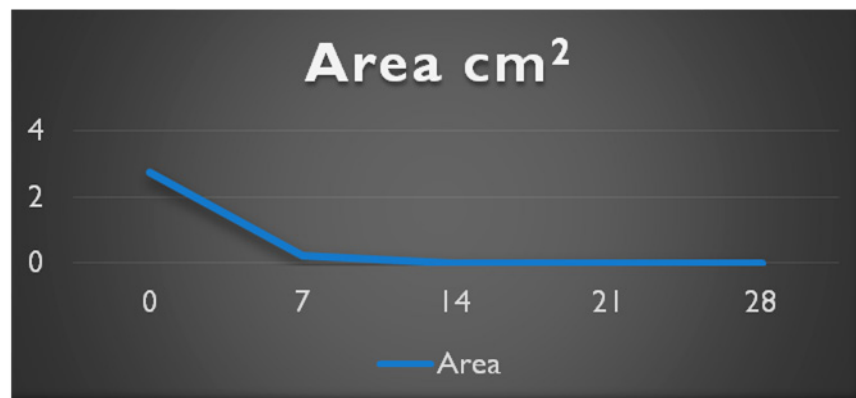
Current Treatments: BioPad



Day 0



Day 28



CASE SERIES

PRESSURE

Age of Patient: 19

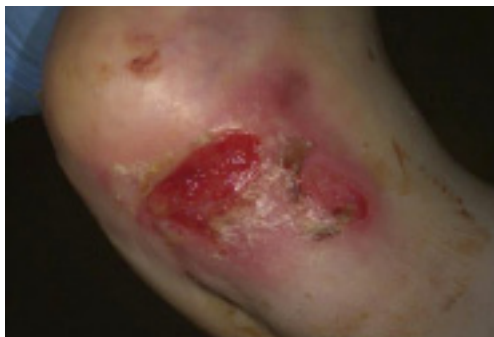Wound Location: Left Heel

Age of Wound: 6 Weeks

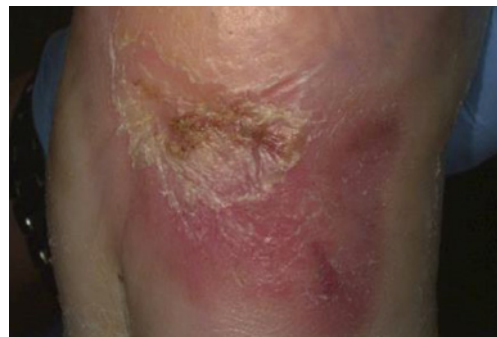Co-morbidities: Spina Bifida, Paraplegic

Previous Treatments: Debridement, Prafo Boot, SOC

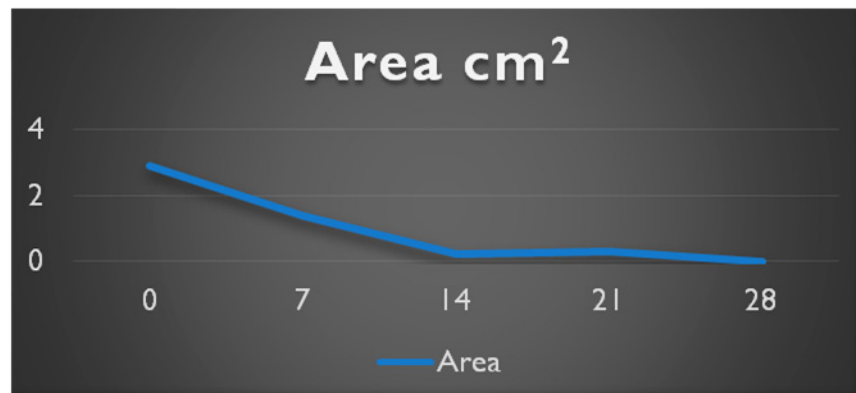
Current Treatments: BioPad, Prafo Boot



Day 0



Day 28



CASE SERIES

PARTICIPATING SITES

Wound Healing & Hyperbaric Center - AGMH Hospital

Kittanning, Pennsylvania

Dr. Keyur Patel, Dr. Bryan Doner, Laura Serena LPN

Wound Clinic-St. Vincent Hospital

Erie, Pennsylvania

Dr. Daniel DiMarco, Debbie Meyers LPN

St. John Wound Center - St. John Medical Center

Tulsa, Oklahoma

Dr. Lam Le, Lindsay Saunders



ANGELINI